

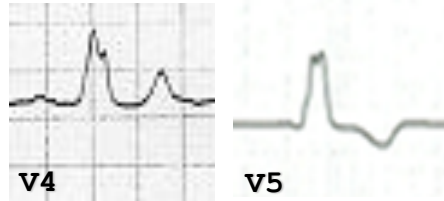
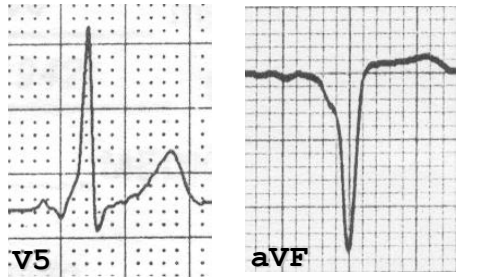
Empastamiento del complejo QRS

Inicial

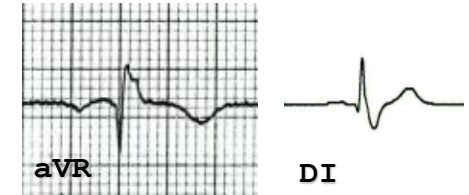
Medio

Terminal

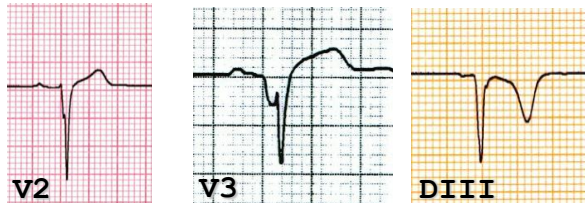
WPW



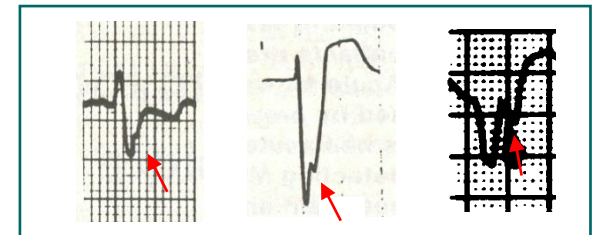
Bloqueos de rama



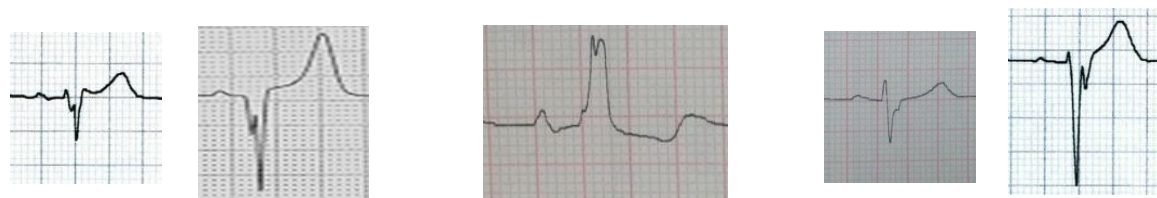
Infarto de miocardio



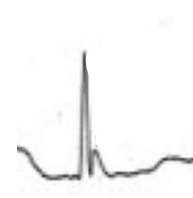Signo de Cabrera



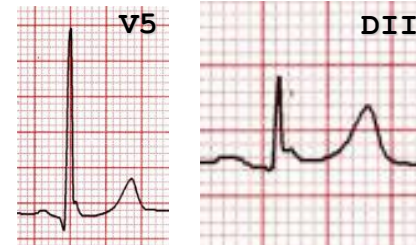
Cardiomiopatía hipertrófica



Onda J



Repolarización precoz



Displasia del VD

