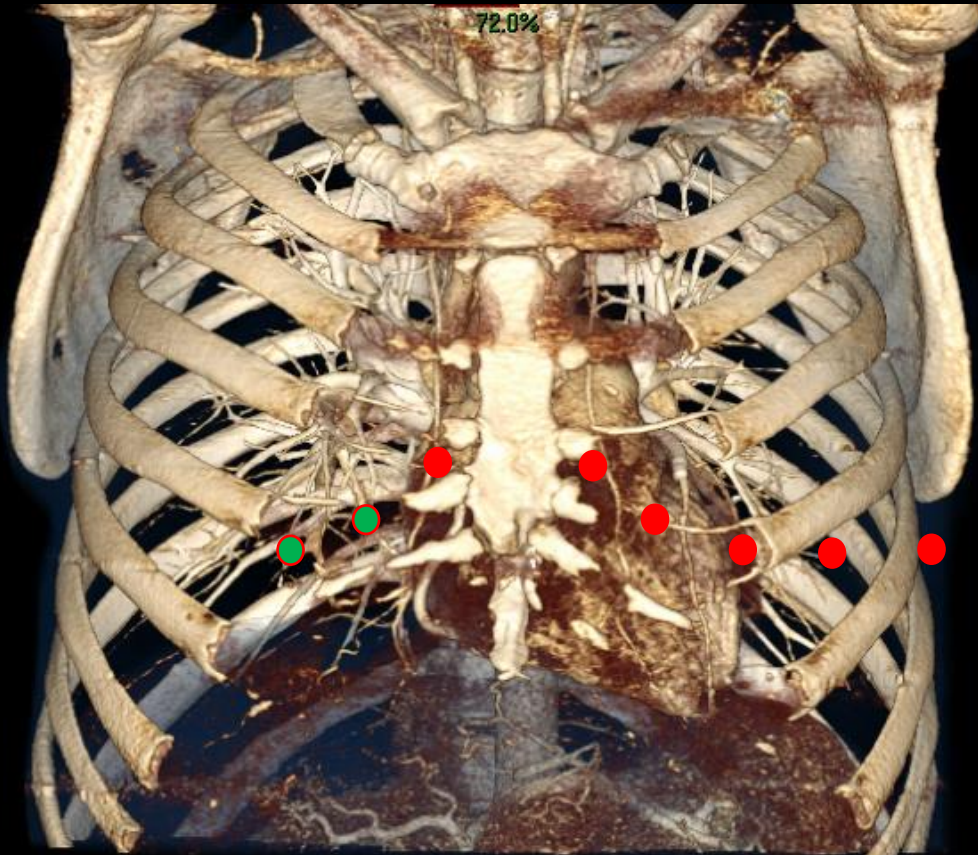
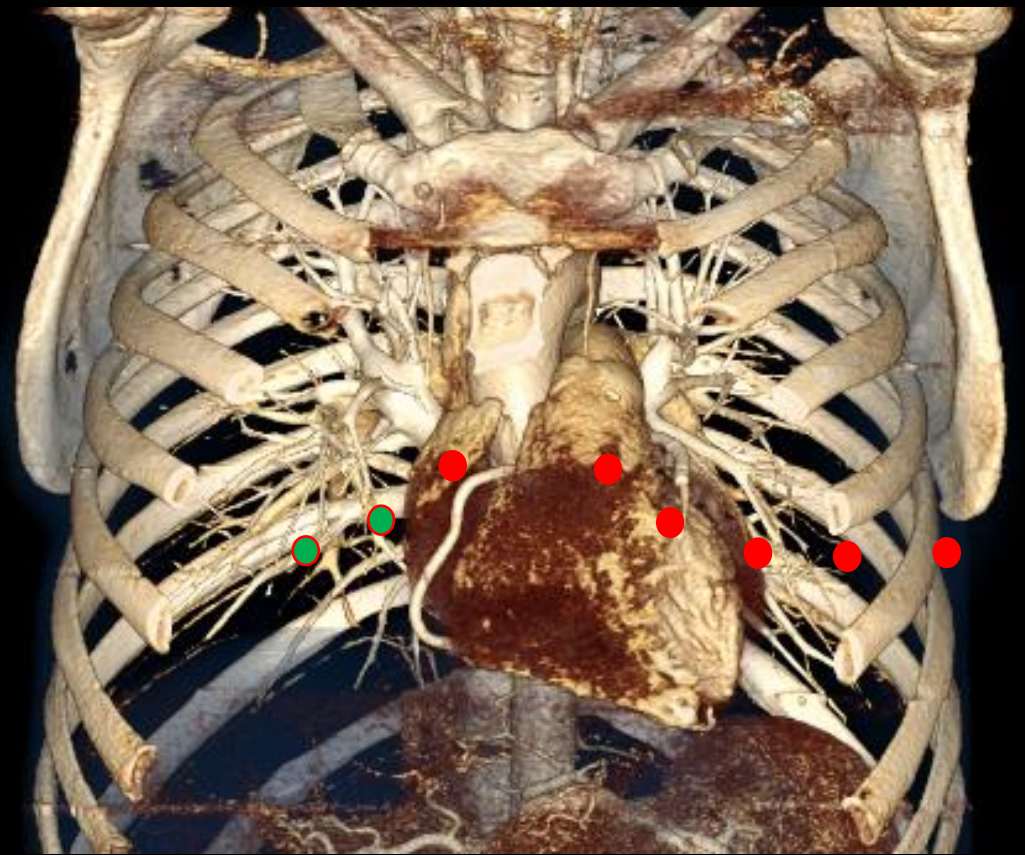


# Vista anterior del tórax

## Derivaciones precordiales derechas



V4R V3R



V4R V3R